

1. Low mood

A 50-year-old woman is taking methotrexate 15 mg once weekly for rheumatoid arthritis. She has developed low mood, poor sleep pattern and early morning wakening.

She wishes to try medication as her symptoms are affecting her ability to work.

Which is the **single most** appropriate medication? Select **one** option only.

- A. Amitriptyline
- B. Citalopram
- C. Lofepamine
- D. Mirtazapine
- E. Venlafaxine

2. Weakness

A 35-year-old woman has noticed increasing weakness and numbness in her legs and arms over the past few days. Today she is feeling short of breath on exertion.

Six weeks ago, she had diarrhoea and stool culture confirmed infection with *Campylobacter jejuni*. She was treated with ciprofloxacin and recovered fully.

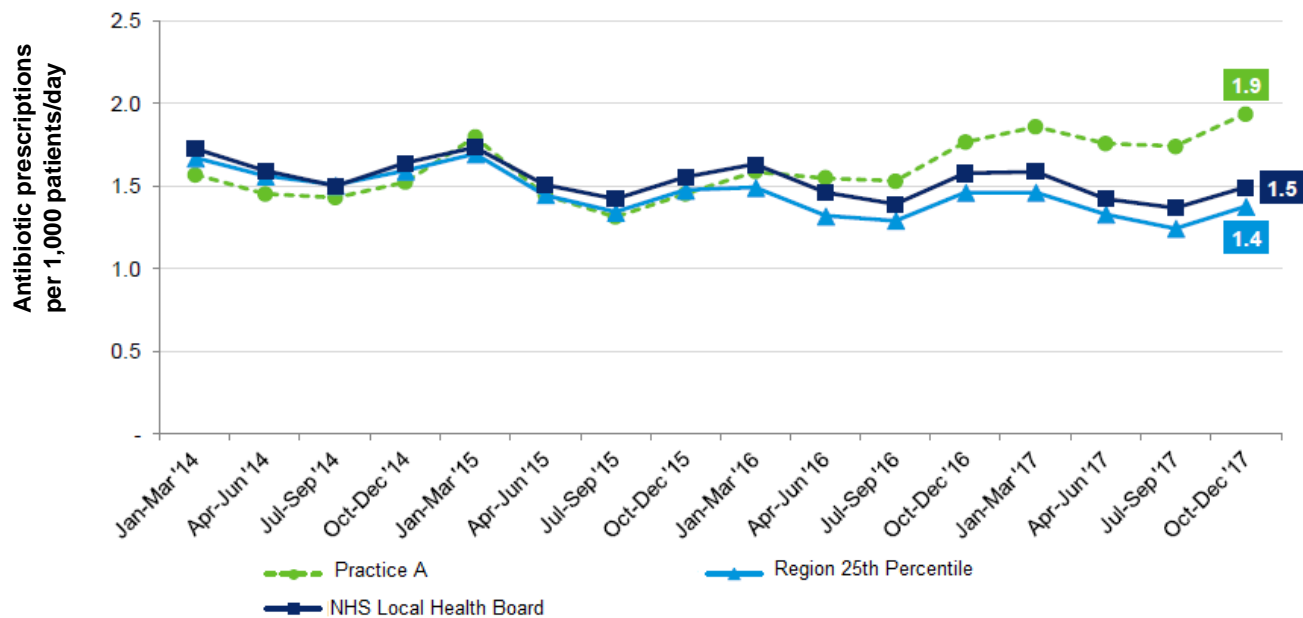
Which is the **single most** likely diagnosis? Select **one** option only.

- A. Drug-induced neuropathy
- B. Guillain-Barré syndrome
- C. Multiple sclerosis
- D. Myasthenia gravis
- E. Transverse myelitis

3. Antibiotic prescribing

Indicator 1: Use of Antibiotics in All Ages

Number of Antibiotic Prescriptions Dispensed per 1,000 Patients per Day



The prescribing information shown is from an NHS Local Health Board (NHS LHB), a Region and Practice A.

Using the data, which is the **single best** interpretation about antibiotic prescribing?

Select **one** option only.

- A. The list size for Practice A has increased
- B. Prescribing trends are consistently higher in the summer months
- C. The NHS LHB prescribing is consistently lower than the Region's 25th centile
- D. The NHS LHB prescribing is more closely aligned to the Region's 25th centile than Practice A's
- E. No conclusion can be drawn

4. Emergency contraception

A 26-year-old woman is day 8 of a 28-day cycle and had unprotected sexual intercourse 12 hours ago. This was the first occasion within this cycle.

She requests levonorgestrel 1.5 mg emergency contraception but also wants to quick-start the combined hormonal contraceptive pill (CHC).

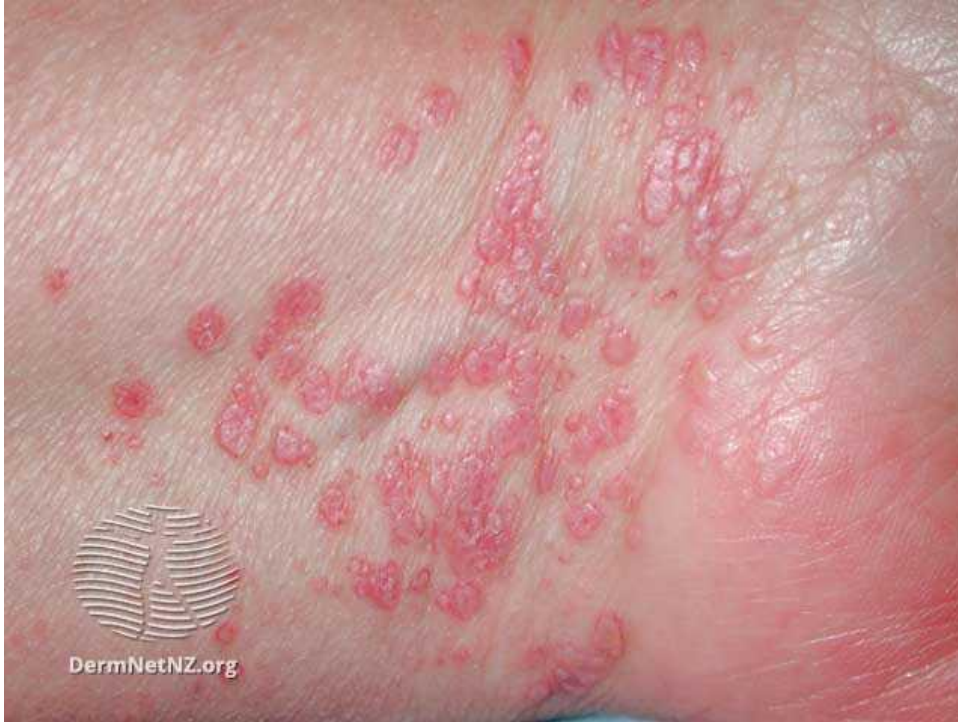Having started the CHC, which is the **single most** appropriate length of time that she needs to take **extra** contraceptive precautions, if any? Select **one** option only.

- A. 24 hours
- B. 5 days
- C. 7 days
- D. 14 days
- E. No additional precautions needed

5. Skin rash

A 45-year-old man has had an intensely itchy rash on his wrists for the past three weeks. The appearance of the rash is as shown.

Which is the **single most** appropriate **first-line** treatment? Select **one** option only.



https://dermnetnz.org/assets/collection/Papular-lichen-planus/papular-lichen-planus-0002__WatermarkedWyJXYXRlcm1hcmtlZCJd.jpg

- A. Betamethasone 0.1% ointment
- B. Calcipotriol cream
- C. Fusidic acid ointment
- D. Permethrin cream
- E. Pimecrolimus 1% cream

6. Hearing loss

A 46-year-old man developed sudden loss of hearing in his right ear six weeks ago. His hearing has not improved at all. He has had no other symptoms and is otherwise well.

Examination of the ear canals and tympanic membranes is normal. A private hearing assessment clinic has confirmed 90% sensorineural hearing loss on the right side.

Which is the **single most** likely diagnosis? Select **one** option only.

- A. Cholesteatoma
- B. Idiopathic
- C. Otosclerosis
- D. Psychosomatic
- E. Ramsey-Hunt syndrome

7. Lethargy

A 50-year-old White man has become increasingly tired and lethargic over the past six months and has developed erectile dysfunction. His wife comments that his skin looks darker even in the winter months.

His blood results are as follows:

		Normal range
Haemoglobin (g/L)	140	
Ferritin ($\mu\text{g/L}$)	1200	30-400
Transferrin saturation (%)	84	<50

Which is the **single most** likely diagnosis? Select **one** option only.

- A. Addison's disease
- B. Chronic active hepatitis
- C. Haemochromatosis
- D. Hypothyroidism
- E. Type 2 diabetes

Respiratory pathogens

For each patient, select the **single most** likely **causative** agent from the list of options.

A	Adenovirus	E	Measles virus
B	Epstein-Barr virus	F	<i>Mycoplasma pneumoniae</i>
C	<i>Group A beta-haemolytic streptococcus</i>	G	Respiratory syncytial virus
D	<i>Legionella pneumophila</i>	H	<i>Streptococcus pneumoniae</i>

8. A 10-month-old girl has had a fever and rhinitis for two days followed by a persistent cough. She has a temperature of 38 °C, respiratory rate over 40/min and fine crackles throughout both lungs.

9. A 15-year-old boy is treated with amoxicillin for a purulent sore throat and high fever. 48 hours later, he develops a widespread, non-blanching maculopapular rash.

10. Risk of hip fracture

A cohort study evaluated the relationship between dietary calcium supplementation and hip fractures in post-menopausal women. 100 women took calcium supplements and 100 women took placebo tablets.

Over the three-year period, five women had hip fractures in the calcium group and ten women had hip fractures in the placebo group.

What is the **risk** of a hip fracture in the **treated** group? Select **one** option only.

- A. 0.01
- B. 0.05
- C. 0.1
- D. 0.5
- E. 1.0

11. Drug dose calculation

A four-year-old girl has recurrent urinary tract infections and the paediatrician has recommended trimethoprim prophylaxis at a dose of 2 mg/kg at night.

She weighs 15 kg and trimethoprim suspension is available as 50 mg/5mls.

What **volume** of suspension (in mls) should the child's mother give her every evening?

Type your answer in the following text box. Use figures **not** words. Percentages and fractions are **not** acceptable.

 mls

12. Retinopathy

13. Pneumonitis

Side effects of rheumatological drugs

For each drug side effect, select the **single most** likely causative drug. Select **one** option only.

- A. Alendronic acid
- B. Allopurinol
- C. Diclofenac
- D. Etoricoxib
- E. Febuxostat
- F. Hydroxychloroquine
- G. Infliximab
- H. Methotrexate

14. Visual disturbance

A 63-year-old man with hypertension suddenly loses the vision in his left eye. Visual acuity is hand movements only on the left and 6/6 on the right.

Fundoscopy of the left eye shows flame-shaped retinal haemorrhages spreading out from the disc.

Which is the **single most** likely diagnosis? Select **one** option only.

- A. Acute glaucoma
- B. Central retinal artery occlusion
- C. Central retinal vein occlusion
- D. Retinal detachment
- E. Vitreous haemorrhage

15. Family history of diabetes

A 47-year-old woman has a screening blood tests because of her family history of type 2 diabetes. Her BMI is 29 kg/m². She feels well.

Her blood test result is as follows:

HbA_{1c} 40 mmol/mol. FBC normal.

Which is the **single most** appropriate interpretation of the result? Select **one** option only.

- A. Impaired fasting glycaemia
- B. Impaired glucose tolerance
- C. Non-diabetic hyperglycaemia (Prediabetes)
- D. Normal
- E. Type 2 diabetes

16. Child development

Specialist referral is **most** appropriate for which **two** of the following children? Select **two** options only.

- A. A four-week-old boy whose mother reports he does not smile
- B. A four-month-old girl who cannot grasp an object when it is placed in her hand
- C. A four-month-old boy who cannot sit unsupported
- D. A two-year-old girl who cannot go down stairs with one foot per step
- E. A two-year-old girl who cannot hop
- F. A three-year-old boy who cannot combine words into a simple sentence

17. Disclosure of medical information

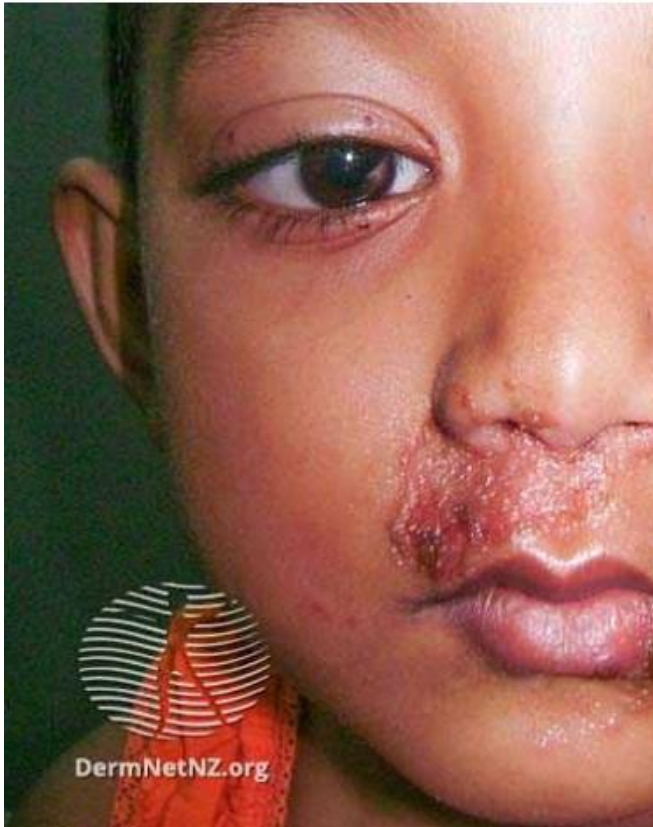A 32-year-old man with alcohol dependence requests a medical report to support his application for rehousing by the local authority. The local authority rejects the application and he now wants to see a copy of the medical report.

In which **two** of the following situations is it **most** appropriate to **deny** disclosure? Select **two** options only.

- A. It may result in a complaint to the practice.
- B. It may reveal information about another patient.
- C. It may upset the patient.
- D. The GP who wrote the report may come to serious harm.
- E. The local authority has not agreed to the disclosure.
- F. The report contains factually incorrect information

18. Skin infections in children

An eight-year-old child has had a localised rash around the nose for two days.



https://dermnetnz.org/assets/collection/Impetigo/impetigo0007__WatermarkedWyJXYXRlcm1hcmtlZCJd.jpg

According to current guidance, which is the **single most** appropriate **minimum** number of days that this child be kept away from school once treatment has started? Select **one** option only.

- A. 1
- B. 2
- C. 3
- D. 5
- E. 7

19. Liver disease

A 28-year-old man had a flu-like illness while on holiday in Thailand last week, with anorexia, nausea and fever. When he was seen yesterday, he was jaundiced but abdominal and general examinations were otherwise normal.

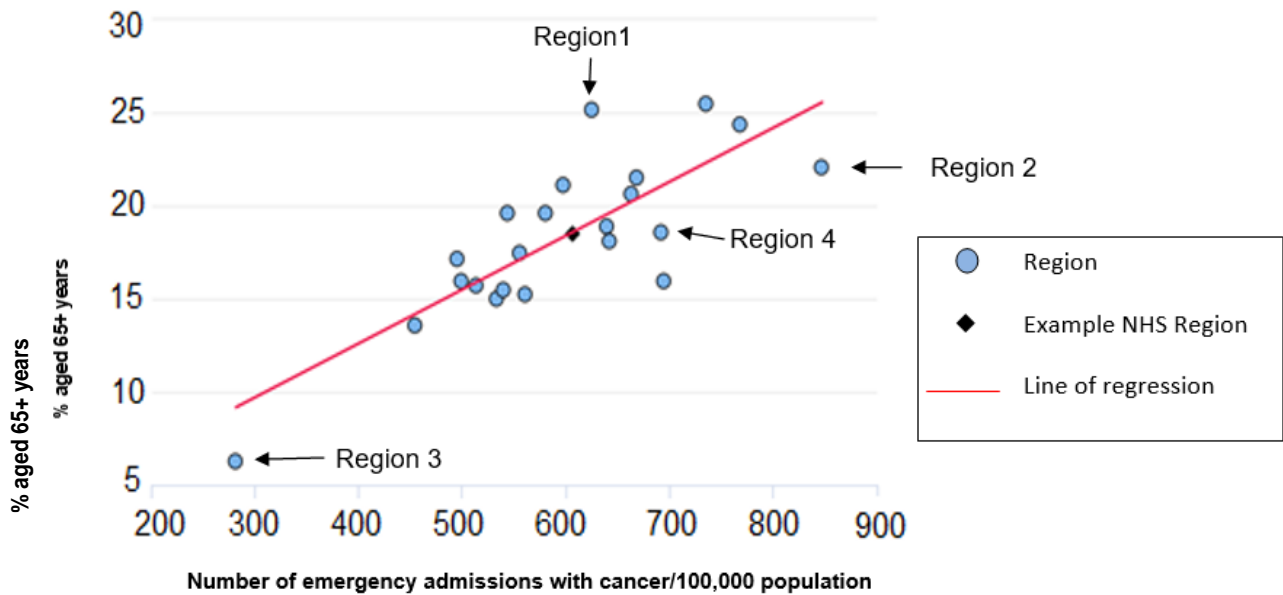
His liver function tests are as follows:

		Normal range
Bilirubin ($\mu\text{mol/L}$)	98	< 17
Aspartate aminotransferase (AST) (IU/L)	228	5 - 42
Alanine aminotransferase (ALT) (IU/L)	186	5 - 42
Alkaline phosphatase (ALP) (IU/L)	302	40 - 150
Albumin (g/L)	35	35 - 50
Total protein (g/L)	73	63 - 80

Which is the **single most** appropriate **specific diagnostic** test for this patient? Select **one** option only.

- A. Anti-nuclear antibodies
- B. Blood alcohol level
- C. Hepatitis A IgM
- D. Hepatitis B IgG
- E. HIV

20. Emergency cancer admissions



Using the data in the figure, which is the **single best** interpretation about emergency admissions with cancer/100,000 population? Select **one** option only.

- A. Region 1 has the highest number of admissions
- B. Region 2 has the highest proportion of elderly admissions
- C. Region 3 has the mean number of admissions
- D. Region 4 has more admissions than the Example NHS Region
- E. No conclusions can be drawn

Risk assessment tools

- A. ABCD²
- B. CHA₂DS₂-VASc
- C. FRAX
- D. QCancer
- E. QRisk[®]3
- F. Wells score
- G. No appropriate risk tool available

For each patient described, select the **single most** appropriate risk assessment tool, if any, from the list of options.

21. A 54-year-old man is diagnosed with atrial fibrillation. His blood pressure is 150/60, pulse is 75/min and irregular and his heart sounds are normal.

22. A 58-year-old woman with breast cancer has chest pain and shortness of breath. Her pulse is regular, 98/min and her heart sounds are normal.

23. Medical standards of fitness to drive

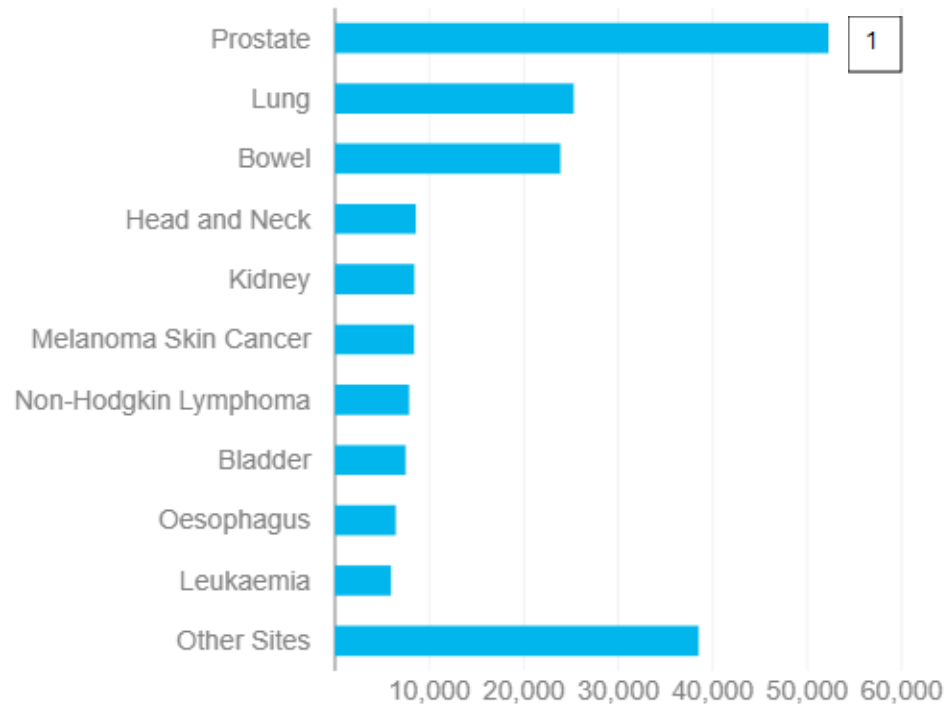
A 65-year-old retired man had an elective coronary artery angioplasty and stent insertion one week ago. He is now well and asymptomatic. He asks you for advice about driving his car.

According to DVLA guidance, which is the **single most** appropriate advice? Select **one** option only.

- A. He may resume driving immediately
- B. He may resume driving after a further week
- C. He may resume driving one month after the angioplasty
- D. He may resume driving six months after the angioplasty
- E. He must inform the DVLA and await their decision before resuming driving

24. Data interpretation

The following graph shows annual average **incidence** rates for common cancers in males in the United Kingdom (2016 – 2018).



Ref: CRUK www.cancerresearchuk.org accessed Nov 2023

Which **single** cancer is represented by the bar labelled 1? Select **one** option only.

- A. Bladder
- B. Colorectal
- C. Lung
- D. Non-Hodgkin's lymphoma
- E. Prostate

25. Management of dyspepsia

A 43-year-old woman with persistent dyspepsia for six weeks has a positive *H. pylori* stool antigen result. She is treated with a one-week course of triple therapy. She is reviewed four weeks later and is symptom free.

Which is the single most appropriate next management option? Select one option only.

- A. Check eradication with *H. pylori* stool antigen test
- B. Check eradication with *H. pylori* breath test
- C. Continue proton-pump inhibitor therapy for further four weeks
- D. Maintenance low-dose proton-pump inhibitor therapy
- E. No further treatment necessary

26. The investigation of failure to conceive

A 25-year-old woman has failed to conceive for three years. She has had recurrent pelvic pain due to endometriosis. Investigations in primary care are as follows:

Full blood count	normal
Thyroid function	normal
Sex hormone profile	normal
Rubella serology	immune
Day 21 progesterone	normal
<i>Chlamydia</i> swab	negative
Pelvic ultrasound	normal

Her partner's semen analysis is reported as normal.

A referral to secondary care is agreed and she asks what is likely to happen next.

According to current guidance, which is the **single most** appropriate **next** investigation?
Select **one** option only.

- A. CT scan pelvis
- B. Hysterosalpingogram
- C. Hysteroscopy
- D. Laparoscopy
- E. Post-coital test

27. Asthma

An 18-year-old woman with asthma has become increasingly wheezy over the past two days. She is unable to complete a sentence in one breath. Examination findings are as follows:

Heart rate	115/min	
Respiratory rate	30/min	
Peak flow	200 L/min	Predicted 450 L/min

According to current guidance, which is the **single most** appropriate description of the **severity** of her asthma? Select **one** option only.

- A. Mild
- B. Moderate
- C. Severe
- D. Life-threatening
- E. Near-fatal

28. Thyroid treatment

A 70-year-old woman with hypothyroidism has been taking levothyroxine 100 mcg daily for the past 30 years. She has had infrequent thyroid function monitoring over that period.

Her TSH level six years ago was 0.3 mU/L and currently it is <0.01 mU/L.

Which **single** condition is she **most** at risk of developing? Select **one** option only.

- A. Hyperparathyroidism
- B. Ischaemic heart disease
- C. Osteopetrosis
- D. Osteoporosis
- E. Paget's disease

29. Injectable contraception with depot medroxyprogesterone acetate (DMPA)

According to UKMEC 2016 guidance, for which **one** of the following conditions is the risk of DMPA **most** likely to outweigh the benefit? Select **one** option only.

- A. Diabetes mellitus
- B. Breast cancer
- C. Previous ovarian cysts
- D. Previous ectopic pregnancy
- E. Current smoker

30. Child growth

A two-month-old girl arrived with her family from Ireland six months ago. She had not seen a health worker and had no immunisations prior to arriving in the UK.

Her routine measurements have fallen from the 50th to below the 25th centile growth line over the past three months. She has a history of minor respiratory infections and recurrent gastroenteritis.

Which is the **single most** appropriate **diagnostic** investigation? Select **one** option only.

- A. Chromosome analysis
- B. Glucose-6-phosphate dehydrogenase level
- C. Jejunal biopsy
- D. Sweat test
- E. Thyroid function test

31. Childhood illness

A seven-year-old girl has a fever associated with a sore throat and loss of appetite. She has small red ulcers in her mouth and itchy spots on the palms of her hands and soles of her feet.

Which is the **single most** likely virus causing her symptoms? Select **one** option only.

- A. Coxsackie A
- B. Herpes simplex
- C. Measles
- D. Parvovirus B19
- E. Varicella-zoster

32. Tiredness

A 50-year-old woman has painful knees. She feels tired and her memory is poor. She has recently lost her appetite, feels nauseated and is constipated. Urinalysis is normal.

Which is the **single most** likely diagnosis? Select **one** option only.

- A. Addison's disease
- B. Chronic renal failure
- C. Conn's syndrome
- D. Cushing's syndrome
- E. Hyperparathyroidism

33. Anal pain

For the past week, a 30-year-old woman has noticed fresh red blood on the toilet paper and experiences sharp pain around the anus when she defecates. Today she can feel a very tender lump at the anal margin.

Which is the **single most** likely diagnosis? Select **one** option only.

- A. Anal fissure
- B. Anorectal abscess
- C. Crohn's disease
- D. Pilonidal abscess
- E. Thrombosed haemorrhoid

Visual problems

- A. Berry aneurysm
- B. Cerebral glioma
- C. Drug-induced
- D. Graves' disease
- E. Guillain-Barré syndrome
- F. Idiopathic intracranial hypertension
- G. Multiple sclerosis
- H. Myasthenia gravis
- I. Optic neuritis
- J. Pituitary adenoma
- K. Stroke

For each patient described, select the **single most** likely diagnosis from the list of options.

34. A 27-year-old woman has severe daily headaches which she describes as pulsatile. Her blood pressure is 130/75 and her BMI is 34 kg/m². She has bilateral papilloedema.

35. A 22-year-old woman has had amenorrhoea for the last four months. She has also been having intermittent headaches but is otherwise well. Confrontational visual field testing shows bilateral temporal hemianopia. Pregnancy test is negative.

36. Adverse drug reactions

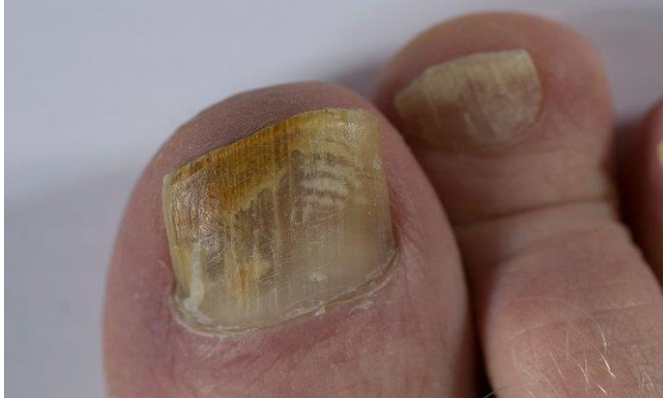A 67-year-old man with known long QT interval has a chest infection that requires antibiotic treatment.

According to the BNF, which **single** antibiotic is **most** important to **avoid** in this situation? Select **one** option only.

- A. Amoxicillin
- B. Ciprofloxacin
- C. Clarithromycin
- D. Co-amoxiclav
- E. Doxycycline

37. Toenail problem

A 53-year-old man complains of discoloured toenails which are causing discomfort. The appearance of the nails is as shown.



Which is the **single most** appropriate **initial** treatment? Select **one** option only.

- A. Oral fluconazole
- B. Oral griseofulvin
- C. Oral terbinafine
- D. Topical clotrimazole
- E. Topical terbinafine

38. Sore throat

A 34-year-old woman has had a sore throat for two days. She has ulcerative colitis which is well controlled with maintenance oral mesalazine.

She has a mild fever of 37.8 °C and has pus on her tonsils.

Which is the **single most** appropriate **initial** investigation? Select **one** option only.

- A. ASO titre
- B. FBC
- C. Liver function tests
- D. Throat swab
- E. Urine for culture

39. Postnatal depression

Which is the **single most** appropriate antidepressant to prescribe to a breastfeeding mother with postnatal depression? Select **one** option only.

- A. Duloxetine
- B. Escitalopram
- C. Fluoxetine
- D. Mirtazapine
- E. Sertraline

40. Cluster headaches

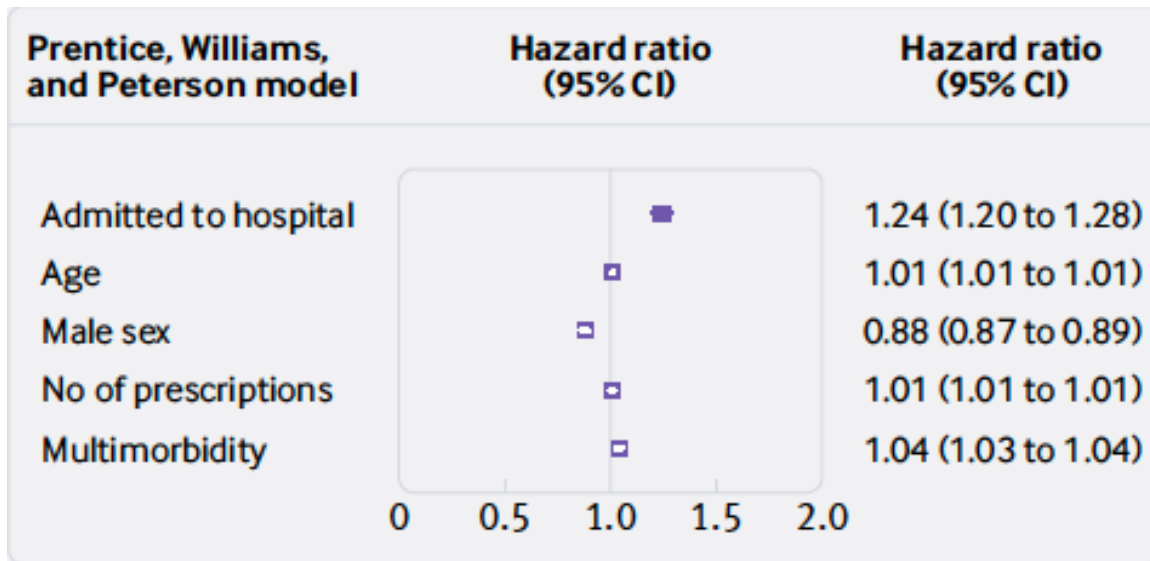
A 45-year-old man has cluster headaches which have failed to respond to sumatriptan. He has attended a specialist headache clinic for further advice.

According to current national guidance, which is the **single most** appropriate **next** treatment for his acute episodes? Select **one** option only.

- A. Fentanyl patch
- B. GTN spray
- C. High flow oxygen
- D. Nasal nicotine
- E. Sublingual buprenorphine

41. Potentially inappropriate prescribing in older people

A study investigated factors associated with potentially inappropriate prescribing in older people. The results are shown below:

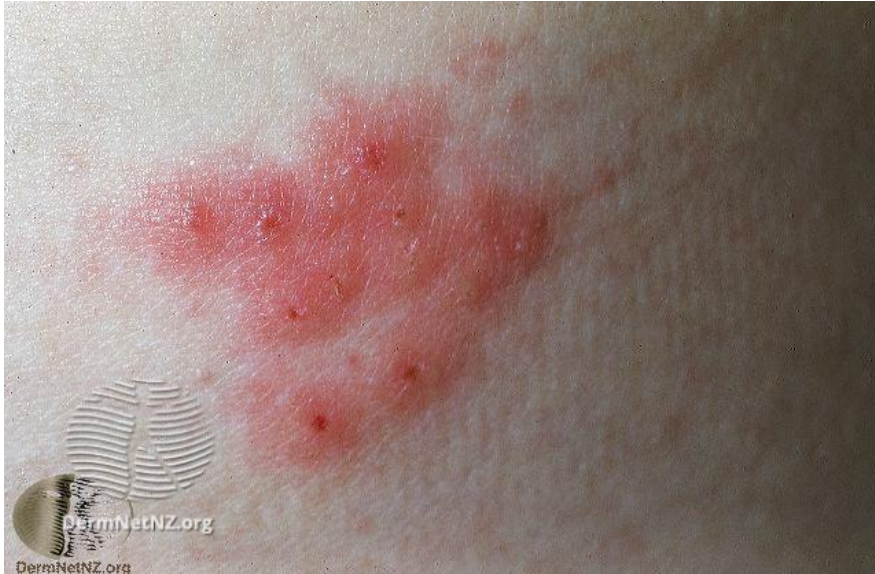

Based on the information given, which is the **single most** statistically significant factor for potentially inappropriate prescribing? Select **one** option only.

- A. Age
- B. Hospital admission
- C. Male sex
- D. Number of prescription items
- E. Multimorbidity

42. Skin rash

A 34-year-old woman has had this rash on her buttock for the past two days. It is sore to touch and she has no rash elsewhere. She says this has happened on at least three previous occasions and the rash is always in the same place.



https://dermnetnz.org/assets/Uploads/2876__WatermarkedWyJXYXRlcm1hcmtlZCJd.jpg

Which is the **single most** likely diagnosis? Select **one** option only.

- A. Coxsackie virus infection
- B. Dermatitis herpetiformis
- C. Herpes simplex
- D. Pompholyx
- E. Shingles

Limping child

- A. Chondromalacia patellae
- B. Developmental dysplasia of the hip
- C. Juvenile arthritis
- D. Non-accidental injury
- E. Osgood-Schlatter's disease
- F. Osteosarcoma
- G. Perthes disease
- H. Septic arthritis
- I. Slipped upper femoral epiphysis
- J. Transient synovitis

For each child described, select the **single most** likely diagnosis from the list of options.

43. A 12-year-old boy has had right thigh and knee pain for about four weeks and has now started limping. He can weight bear, has normal knee movements but has reduced internal rotation of his right hip.

His BMI is 28 kg/m². His temperature is 37.1 °C.

44. A five-year-old girl had chickenpox two weeks ago. She is now limping and complaining of pain in her left leg. Her temperature is 37.4 °C and she has a full range of movement of the left knee and hip.

45. Atrial fibrillation

A 62-year-old man has heart failure due to left ventricular dysfunction. He is seen for annual routine review.

His pulse is 96/min and irregular and his blood pressure is 135/72.

An ECG confirms a new diagnosis of atrial fibrillation.

Which is the **single most** appropriate **initial** medication, if any, to control his heart **rate**? Select **one** option only.

- A. Bisoprolol
- B. Digoxin
- C. Sotalol
- D. Verapamil
- E. No rate-control treatment required

46. Constipation

A 92-year-old woman who lives alone and cares for herself, has long-standing constipation. She has no rectal bleeding or pain, her weight is steady, abdominal and rectal examinations are normal and she is otherwise well.

Which is the **single most** likely cause of her constipation? Select **one** option only.

- A. Alzheimer's disease
- B. Carcinoma of the colon
- C. Diverticular disease
- D. Hypothyroidism
- E. Poor fibre intake

47. Respiratory symptoms

A 34-year-old man has a persistent cough and wheeze following a viral infection four weeks ago. He is a non-smoker.

His peak expiratory flow rate is 500 L/min (expected range 580-620 L/min). A diagnosis of asthma is being questioned.

According to SIGN/BTS guidance, which is the **single most** appropriate inhaled medication to trial? Select **one** option only.

- A. Beclomethasone
- B. Ipratropium
- C. Salbutamol
- D. Salmeterol and fluticasone
- E. Tiotropium

48. Nocturia

A 67-year-old man has nocturia and post-micturition dribbling which is interfering with his sleep. He has an International Prostate Symptom Score of 9, which is in the moderate range (8 to 19).

Clinical examination and investigations are in keeping with benign prostatic hyperplasia with a minor degree of prostate enlargement.

Which is the **single most** appropriate **initial** treatment? Select **one** option only.

- A. Duloxetine
- B. Finasteride
- C. Oxybutynin
- D. Solifenacin
- E. Tamsulosin

49. Chronic kidney disease Stage 3 (CKD3)

A 64-year-old woman with CKD3 and hypertension has an annual review. Her average BP on home monitoring is 143/84. She is currently taking amlodipine 5 mg and atorvastatin 20 mg daily.

Her renal function is stable with an eGFR of 54 ml/min and her urinary albumin:creatinine ratio is 45 mg/mmol (normal range < 3 mg/mmol).

Which is the **single most** appropriate **additional** drug treatment, if any? Select **one** option only.

- A. Aspirin
- B. Clopidogrel
- C. Indapamide
- D. No additional drug therapy indicated
- E. Ramipril

50. Sickle cell disease

A couple have just undergone screening for sickle cell disease in pregnancy and both are found to be carriers.

What is the **risk** of their child having sickle cell disease? Select **one** option only.

- A. 0%
- B. 25%
- C. 50%
- D. 75%
- E. 100%

51. Anticoagulant therapy

An 84-year-old man has just undergone mitral valve replacement with a mechanical valve.

Which is the **single most** appropriate anticoagulant? Select **one** option only.

- A. Apixaban
- B. Aspirin
- C. Clopidogrel
- D. Dabigatran
- E. Warfarin

52. Psychiatric medication

A 45-year-old woman is admitted to hospital with an acute depressive episode. She is started on medication. She suddenly develops shivering, sweating, diarrhoea and confusion.

Which is the **single most** likely drug to have been started? Select **one** option only.

- A. Fluoxetine
- B. Lithium
- C. Mirtazapine
- D. Trazodone
- E. Valproate

53. End-of-life care

According to the current BNF, which is the **single most** appropriate anti-emetic to use in a syringe driver with diamorphine? Select **one** option only.

- A. Domperidone
- B. Glycopyrronium bromide
- C. Levomepromazine
- D. Ondansetron
- E. Prochlorperazine